

Electrical Storm

Fouad Khalil, MD

Cardiology Fellow

UNMC



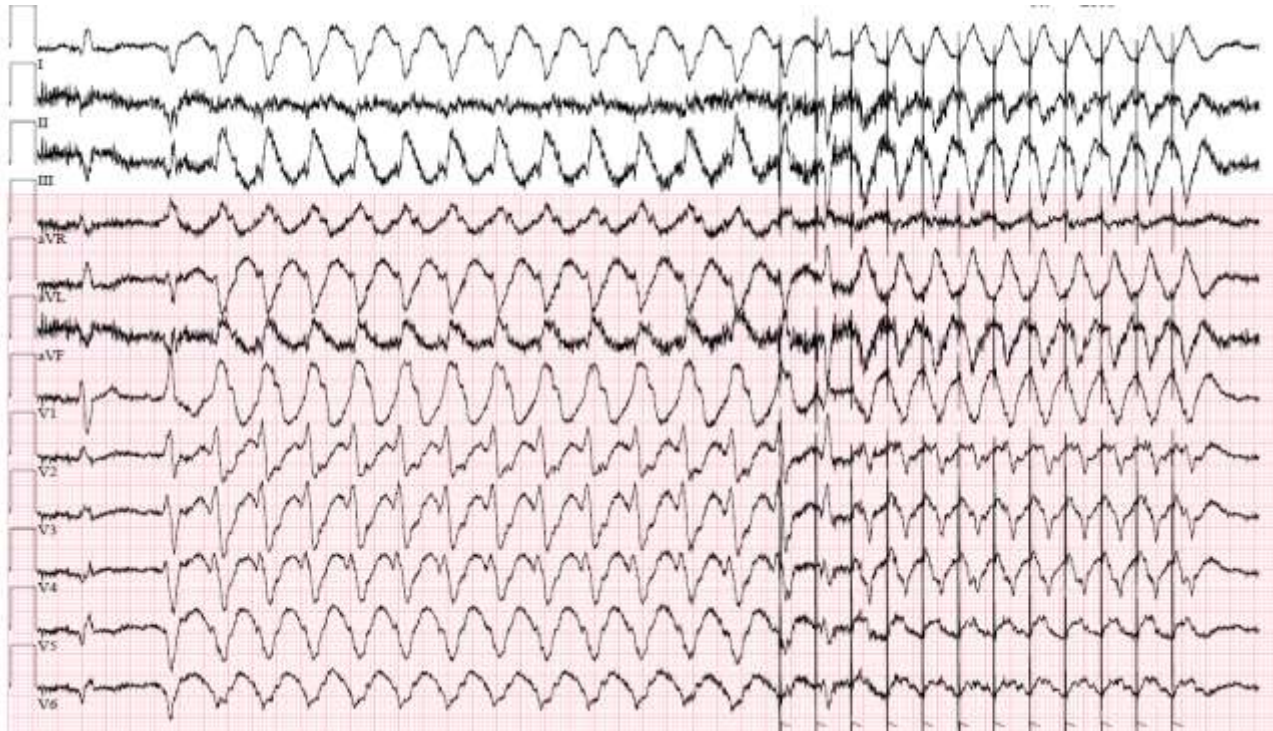
Disclosures

Nothing to disclose.



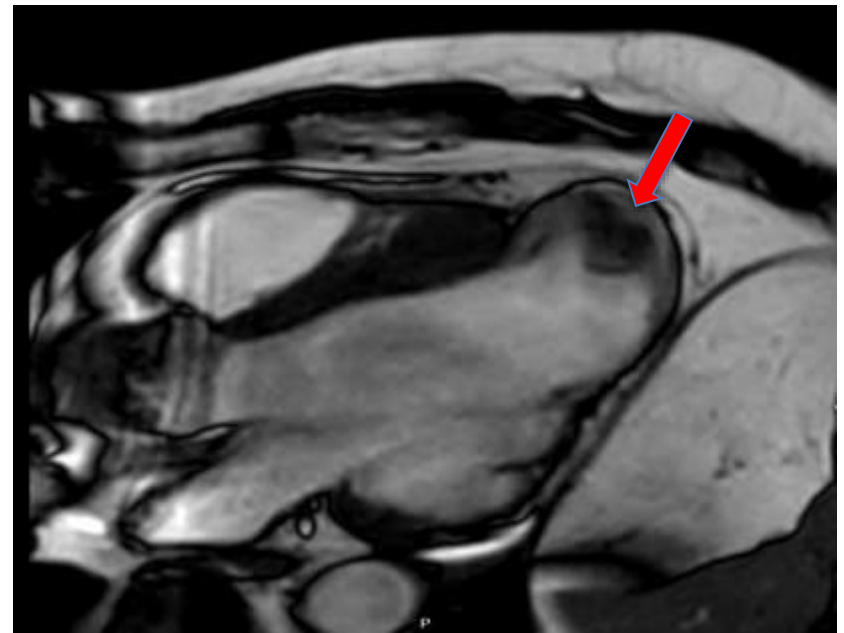
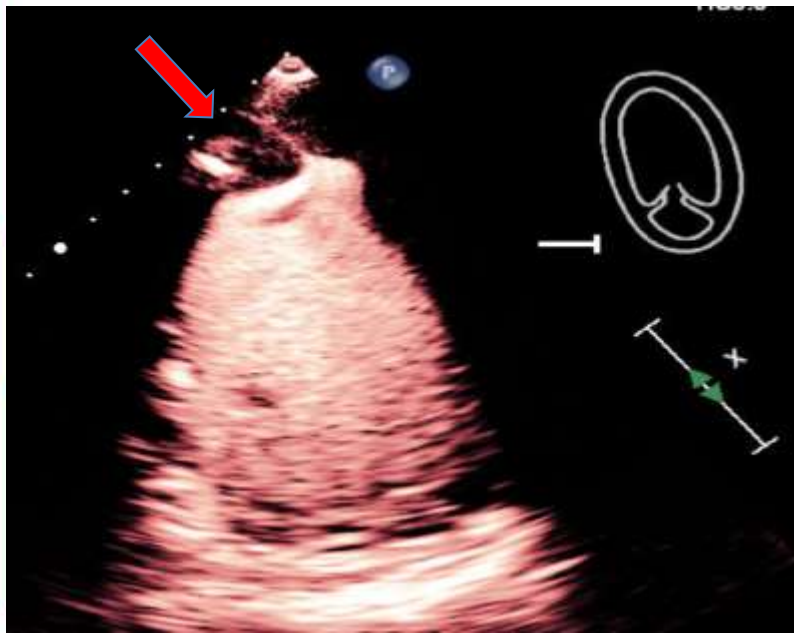
Case Presentation

A 64-year-old male with history of ICM, HFrEF, s/p ICD, initially presented in 2018 with ICD shocks. Failed multiple AADs. Underwent substrate-based ablation of septal scar. Presented in 2024 with several ICD shocks.

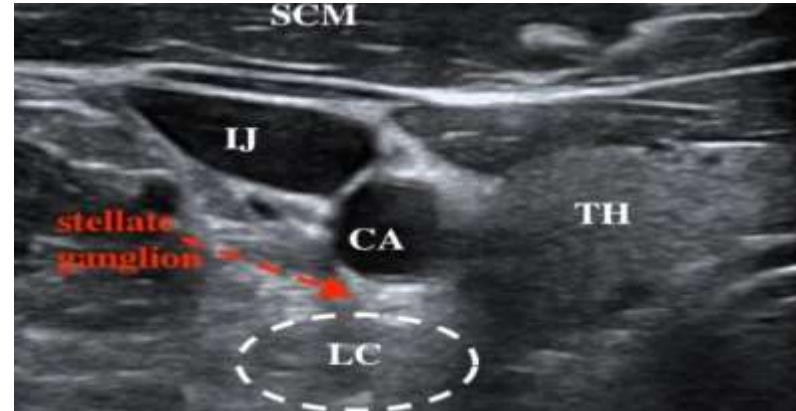
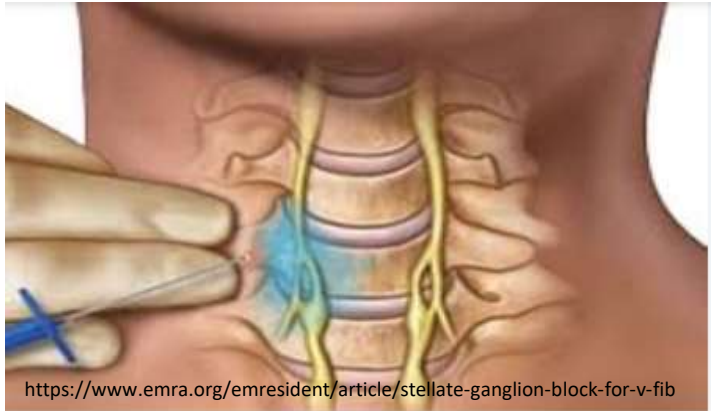


- Started on IV amiodarone → lidocaine → procainamide.
- Dexmedetomidine
- Metoprolol
- Device reprogramming

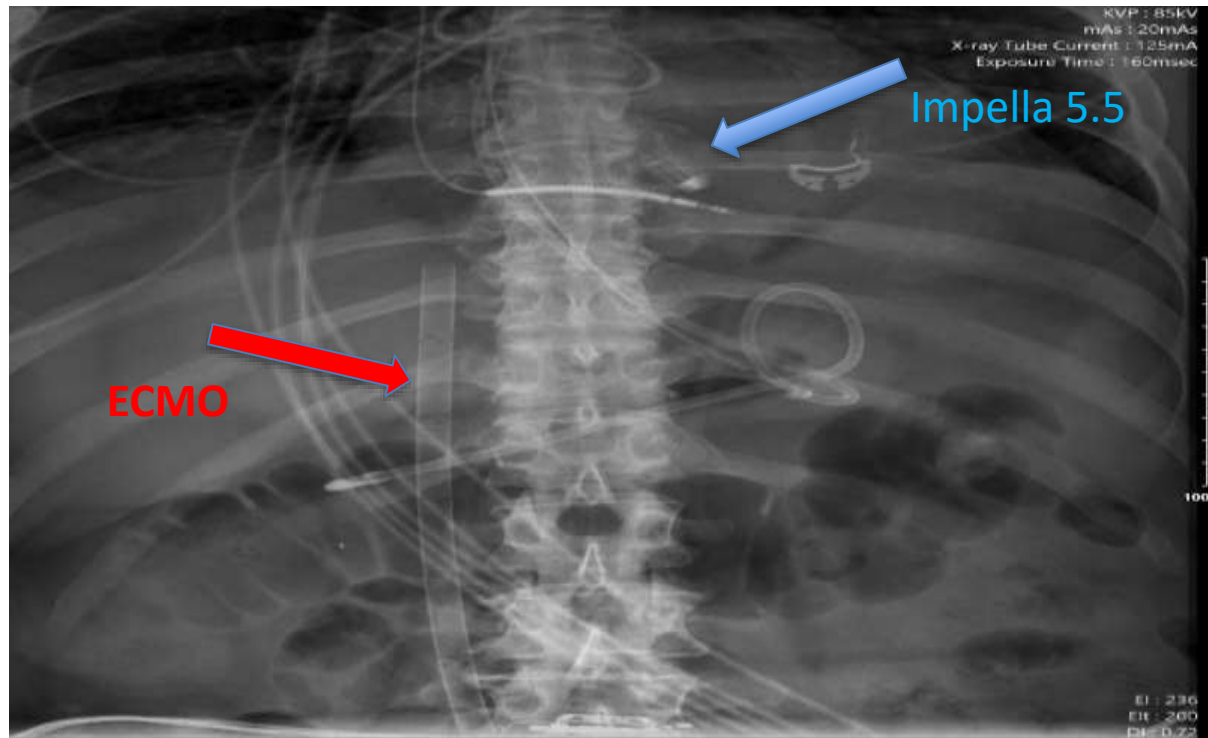
Urgent VT ablation

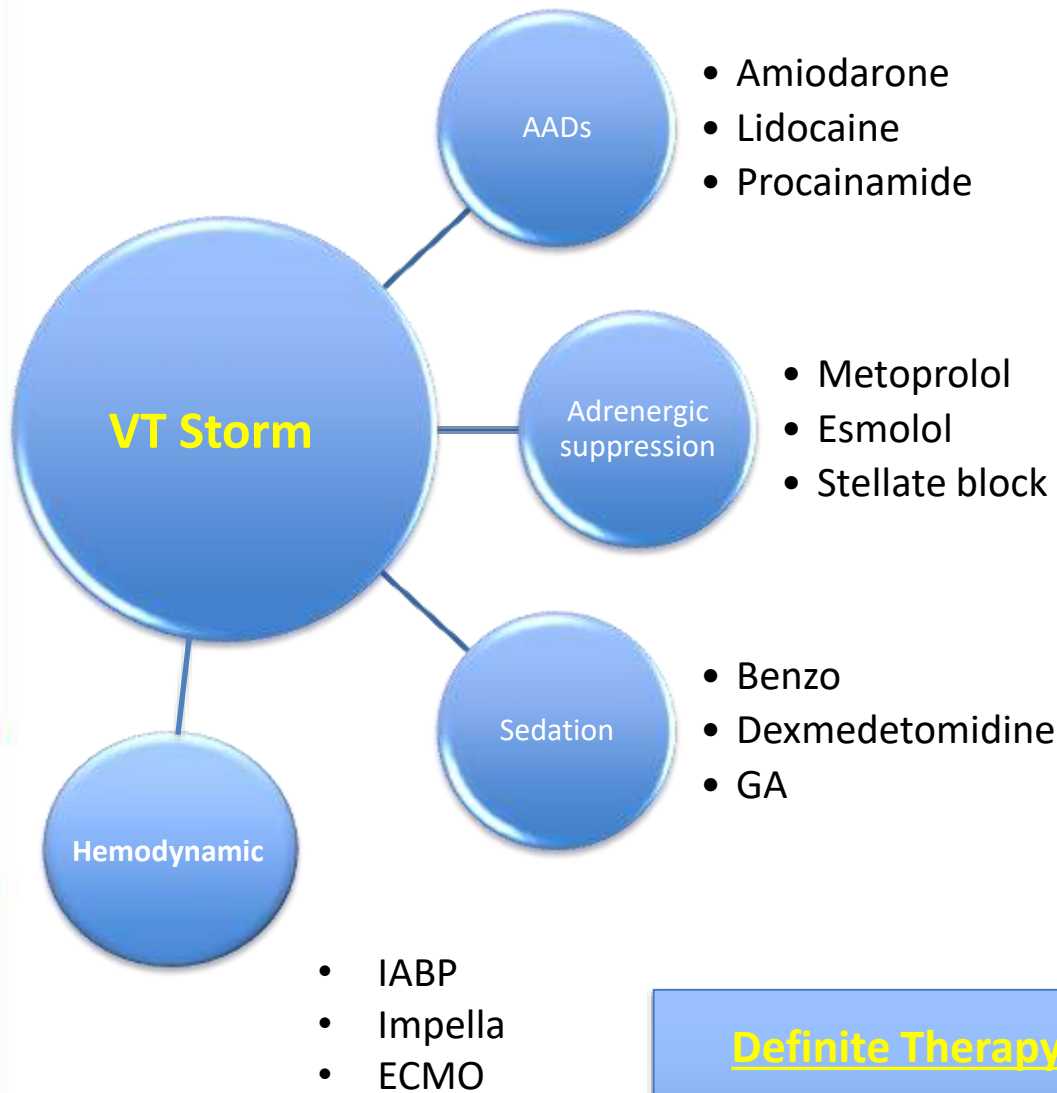


Stellate ganglion block



ECMO cannulation and axillary Impella





Definite Therapy

- Ablation
- OHT/VAD
- Palliative

- Electrophysiology
- ICU/CCA
- MMI
- Advanced HF
- Interventional
- Cardiothoracic surgery
- Palliative



Thank you !

