

A day in the life of a laryngologist

Jayne Dowdall, MD

Disclosures

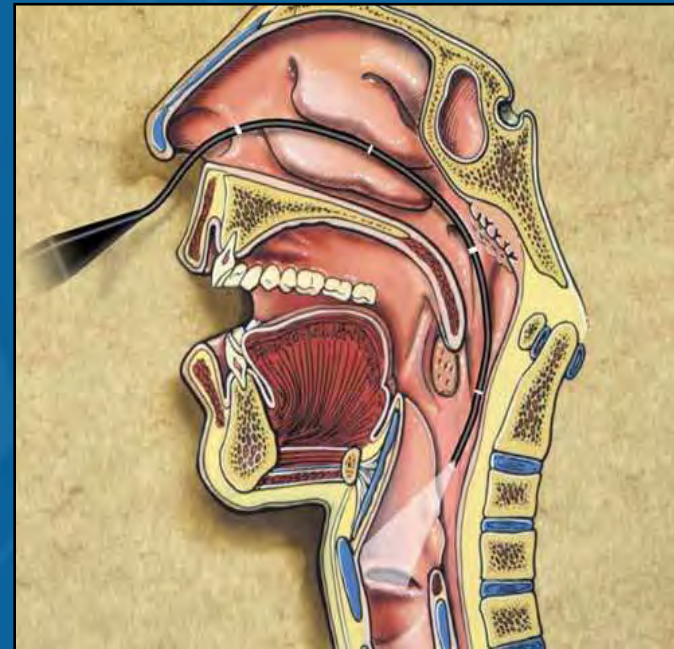
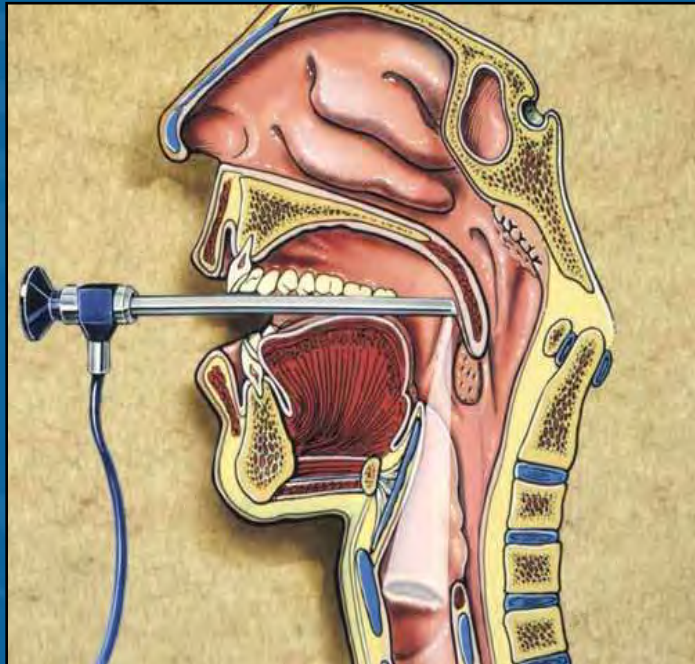
- Airway Education, LLC
- Amplified Resonance, LLC

Learning Objectives

- When to refer
- Modalities for exams

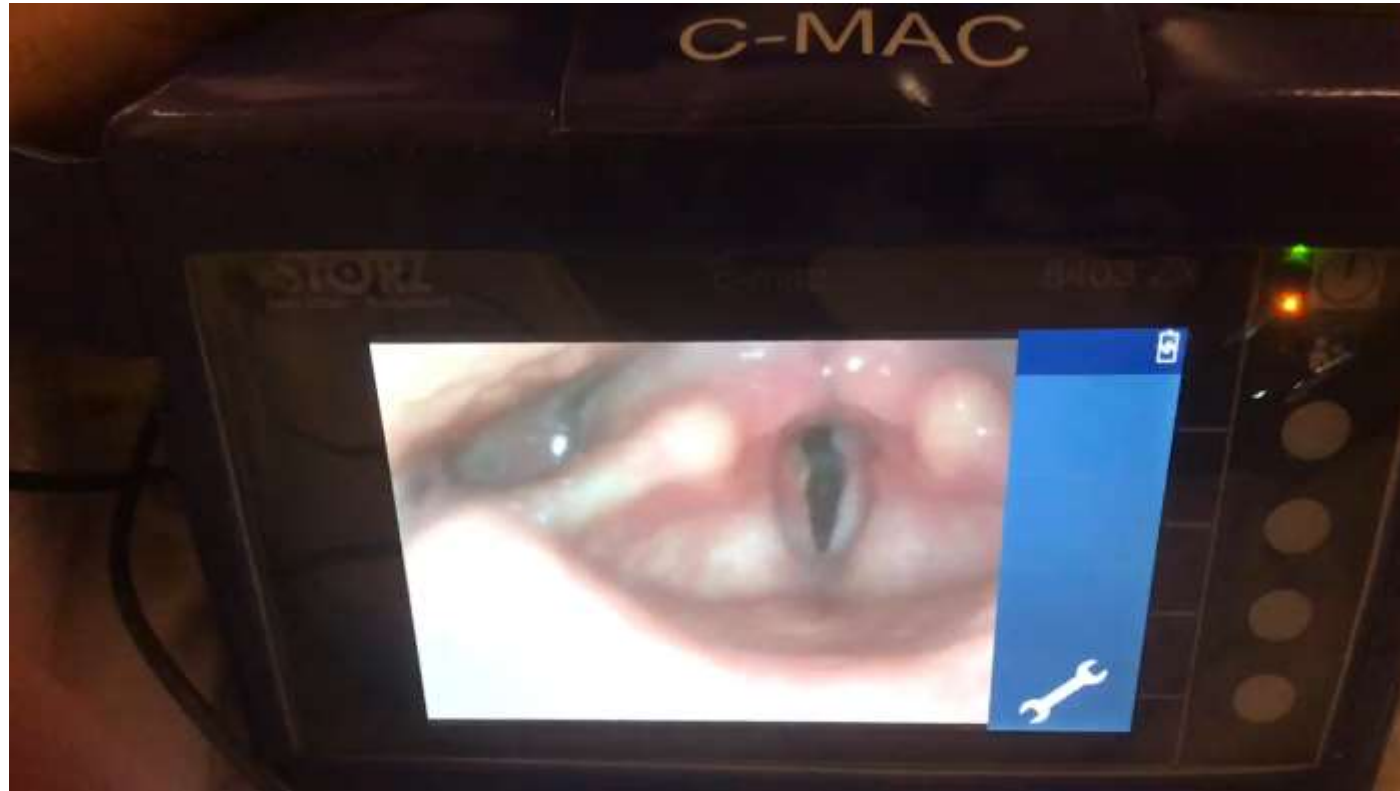Laryngeal Examination

- Performed by an Ear, Nose and Throat Doctor (Otolaryngologist), Laryngologist or Speech Language Pathologist (SLP)
 - Looking at throat through mouth or nose



Case 1

- 30 year old female s/p intubation in the field for MVC
- 25 weeks pregnant



FREQ: --- Hz

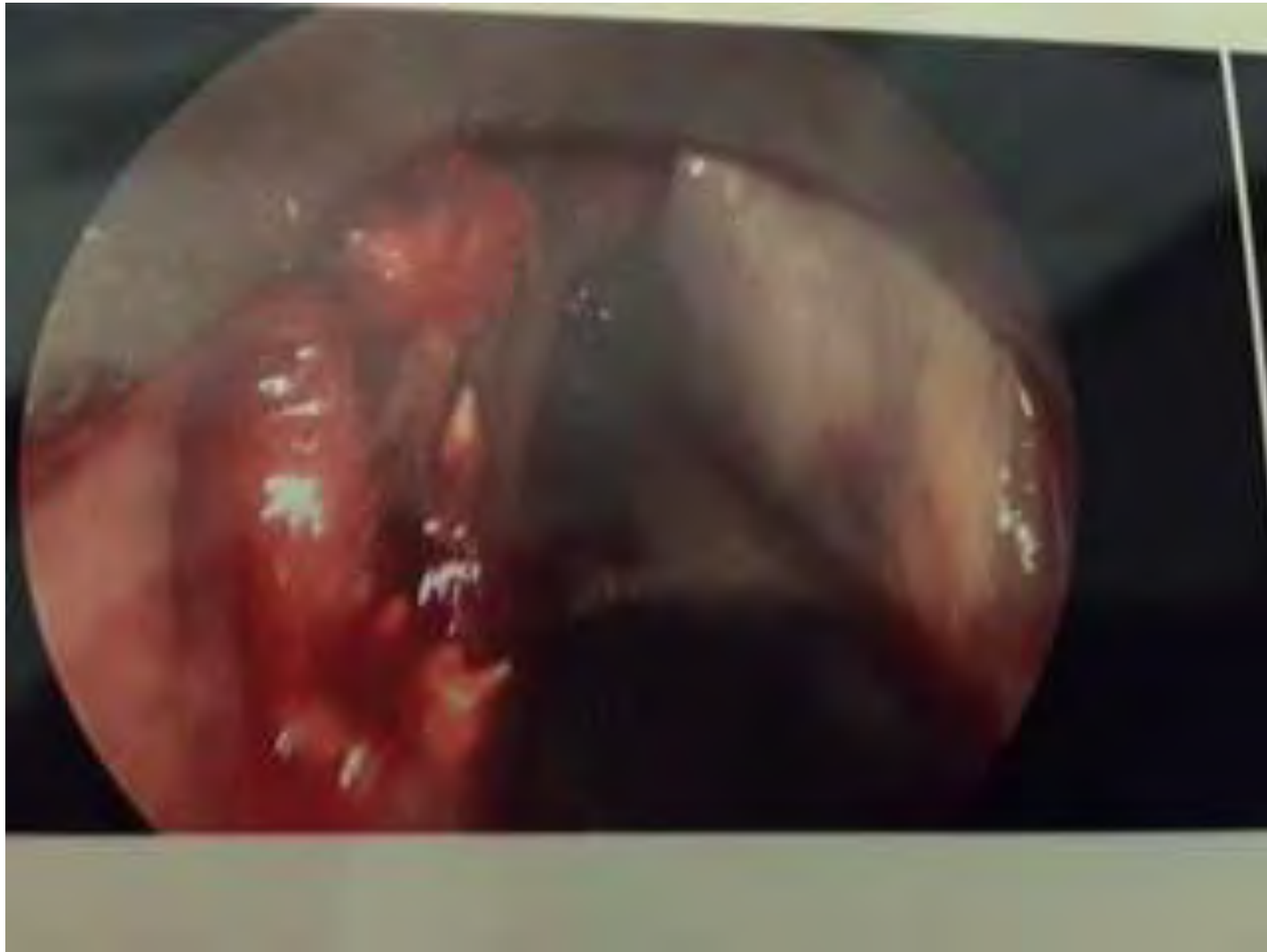AMP: --- dB



SE:+4

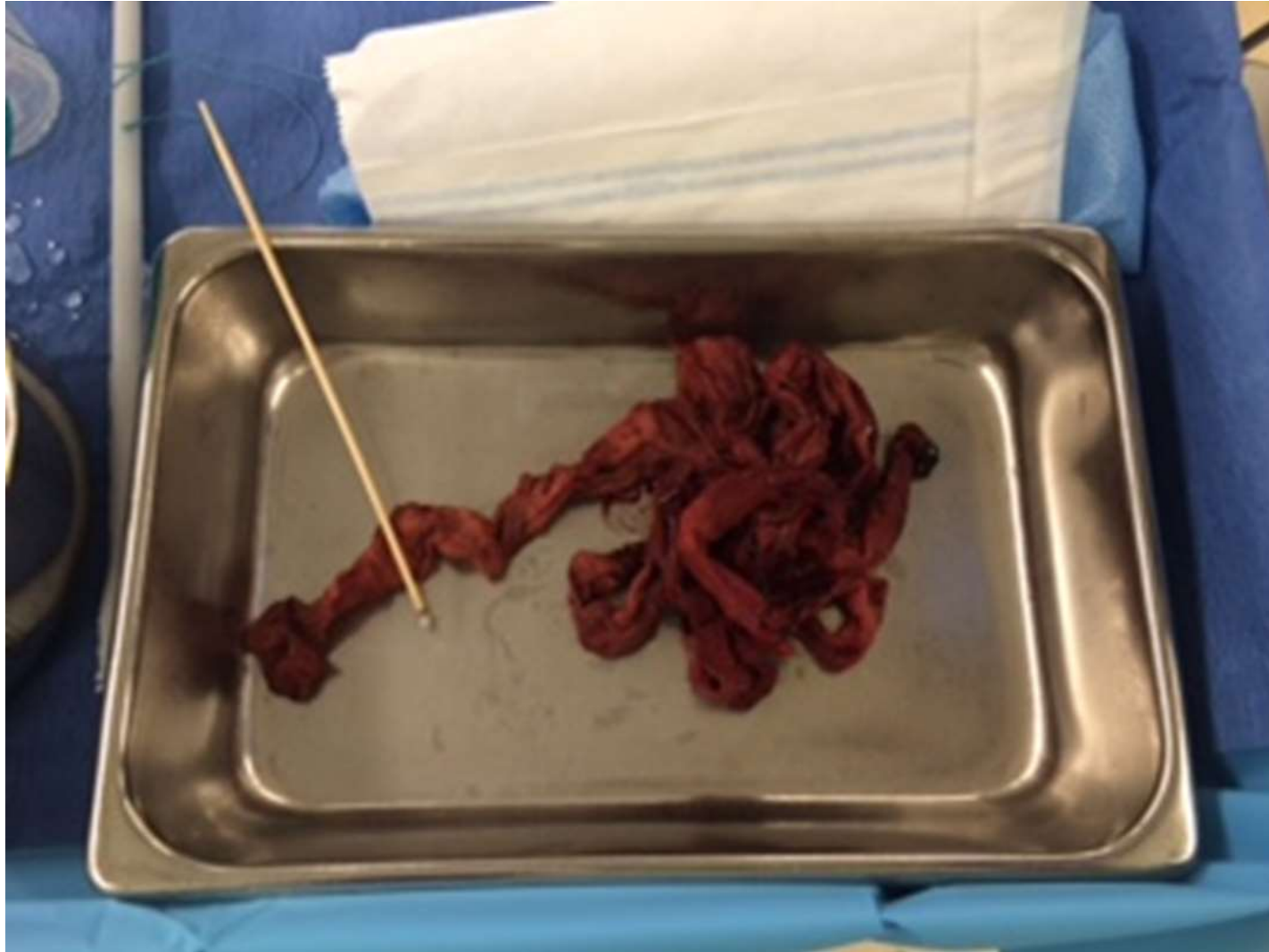Case 2

- Called to PACU – hemorrhage from mouth after extubation



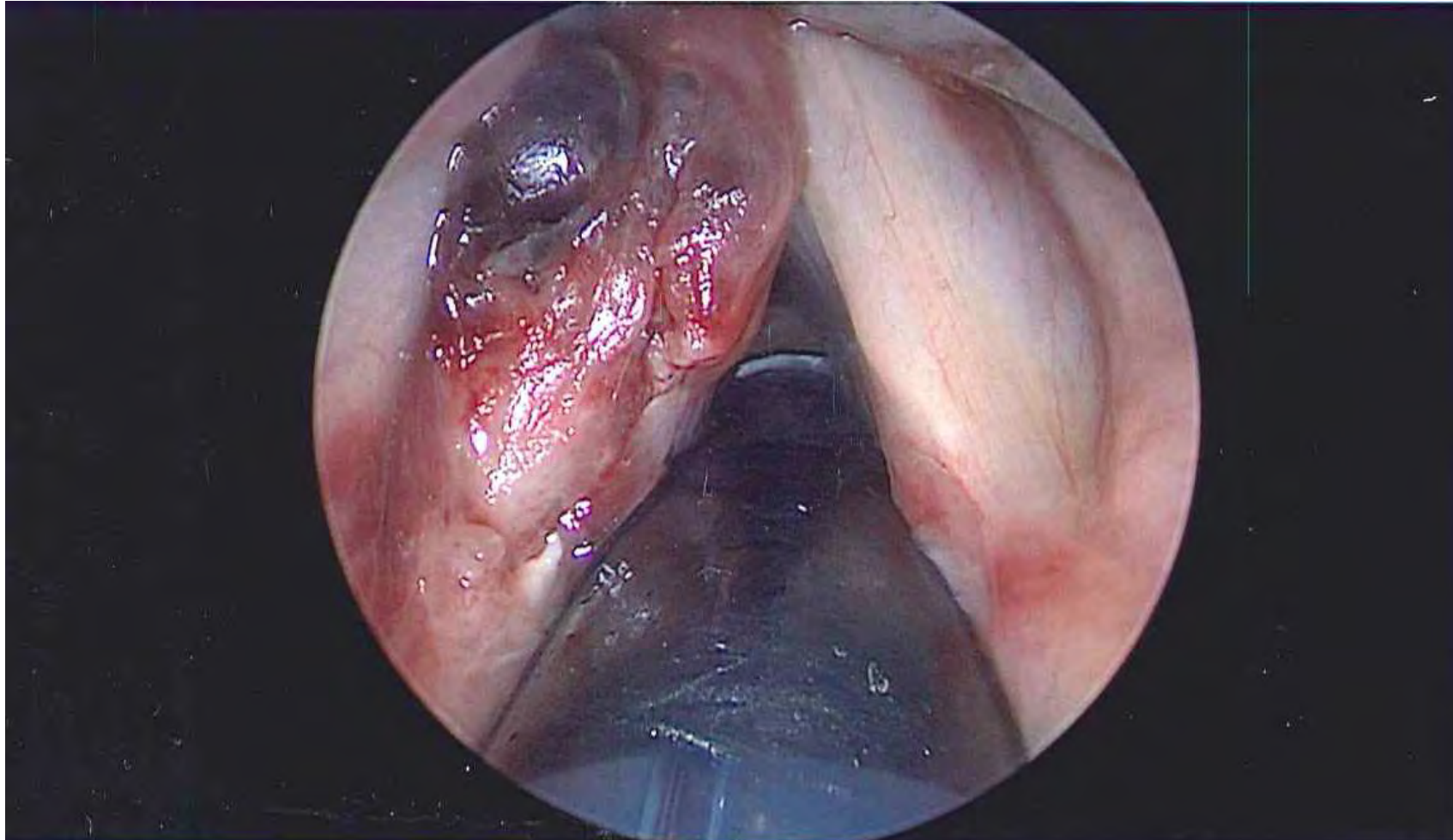
Case 2

- Called to PACU – hemorrhage from mouth after extubation



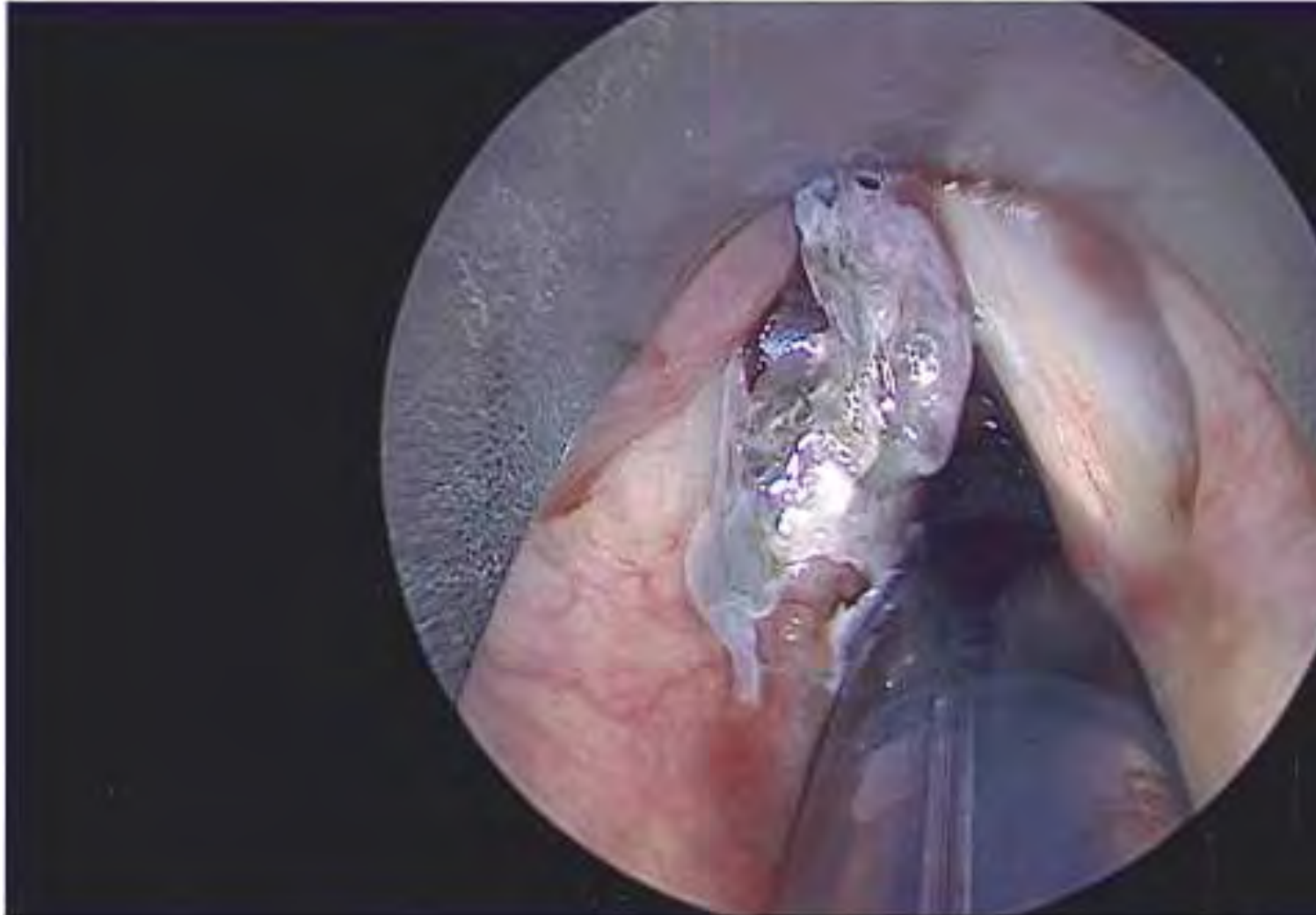
Case 2

- Called to PACU – hemorrhage from mouth after extubation



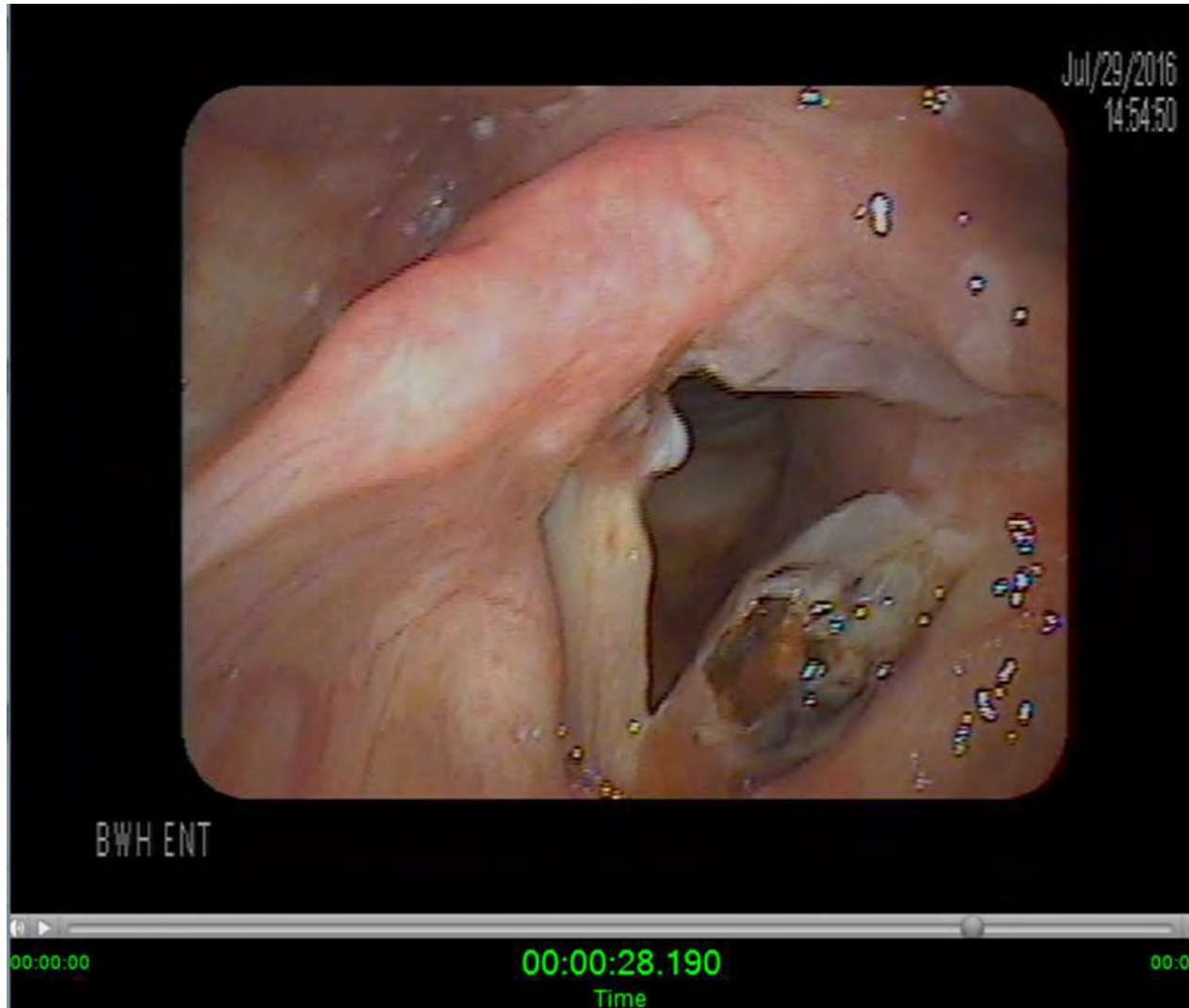
Case 2

- Called to PACU – hemorrhage from mouth after extubation



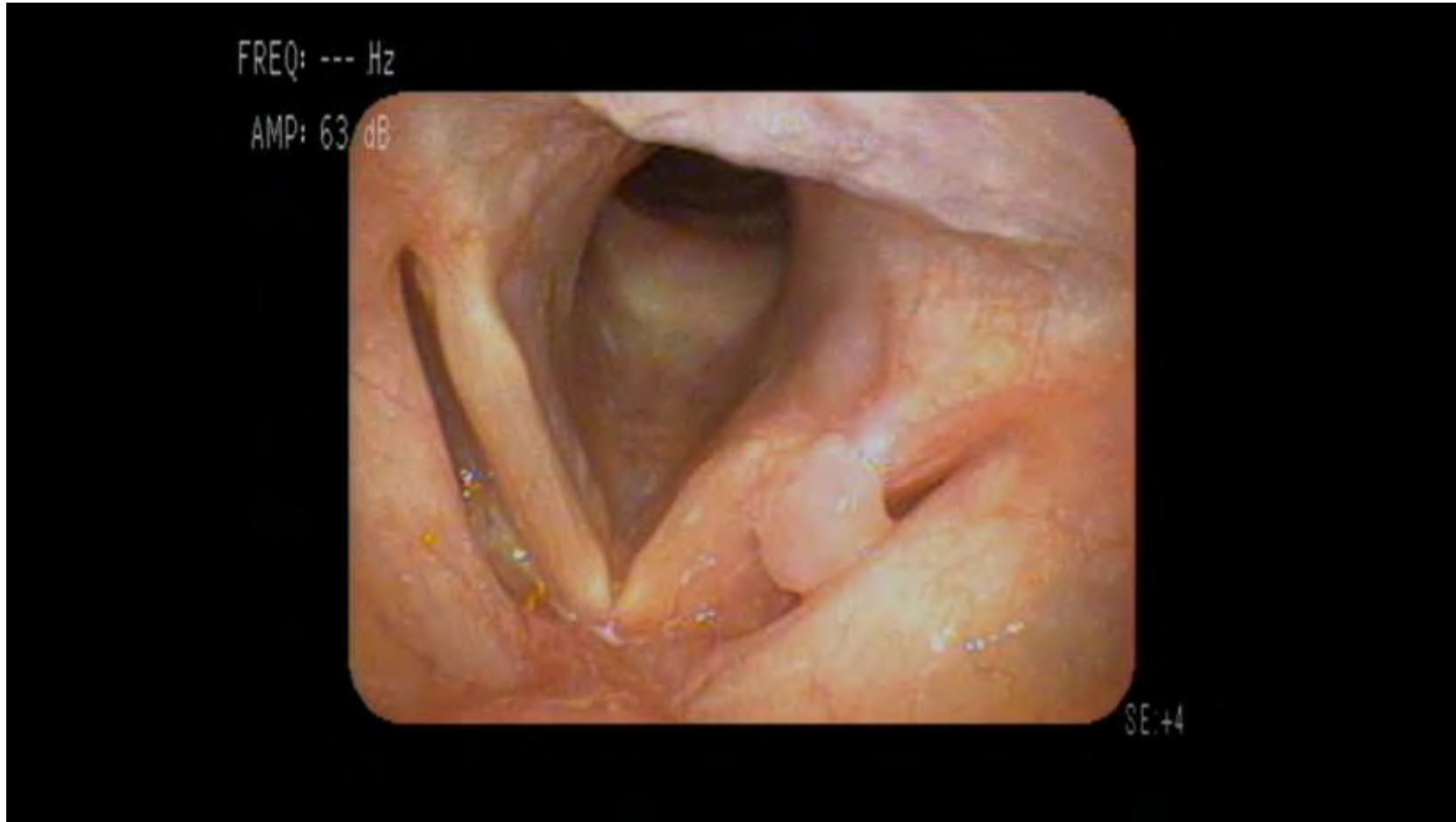
Case 2

- Called to PACU – hemorrhage from mouth after extubation



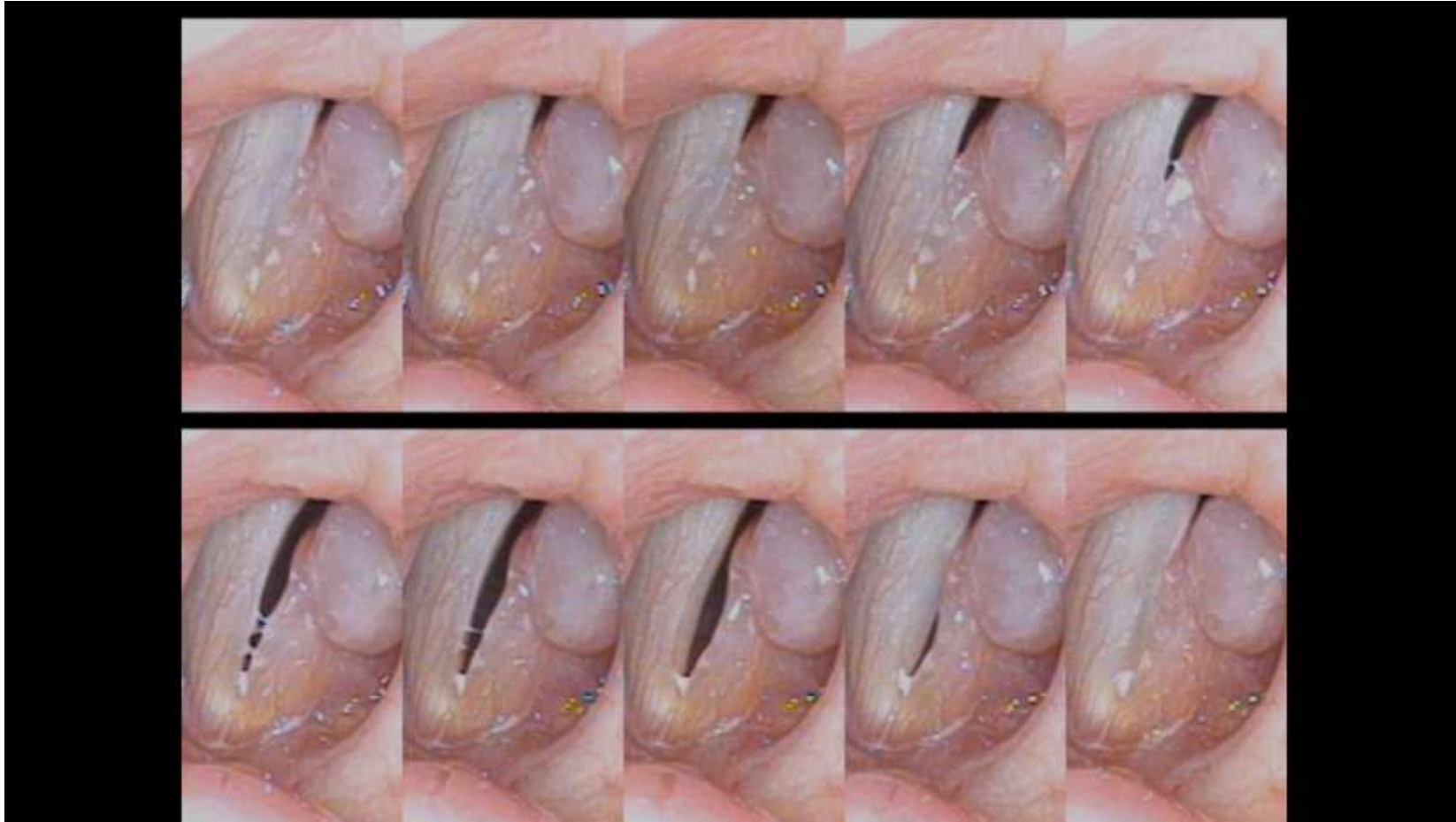Case 2

- Called to PACU – hemorrhage from mouth after extubation



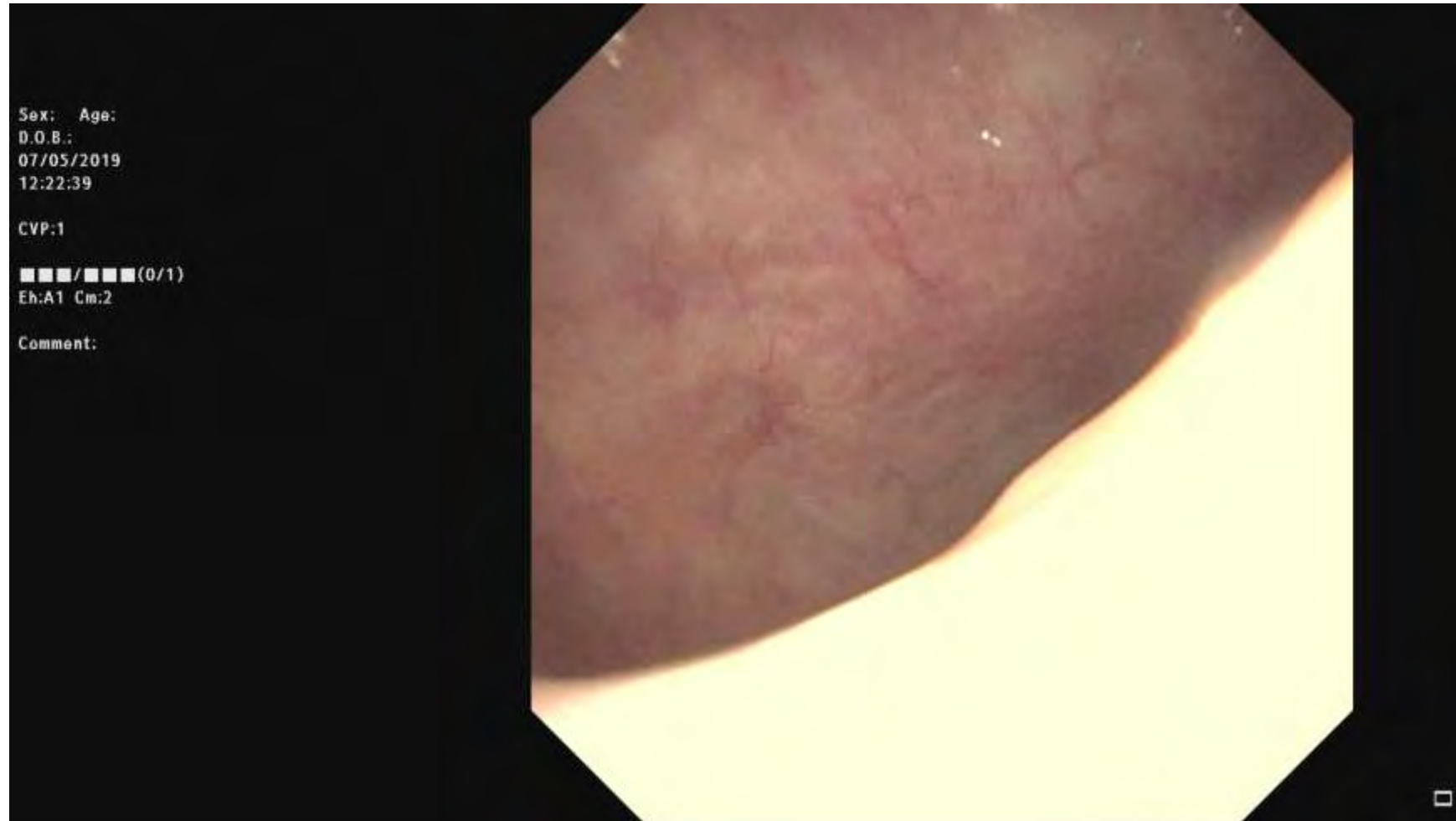
Case 2

- Called to PACU – hemorrhage from mouth after extubation



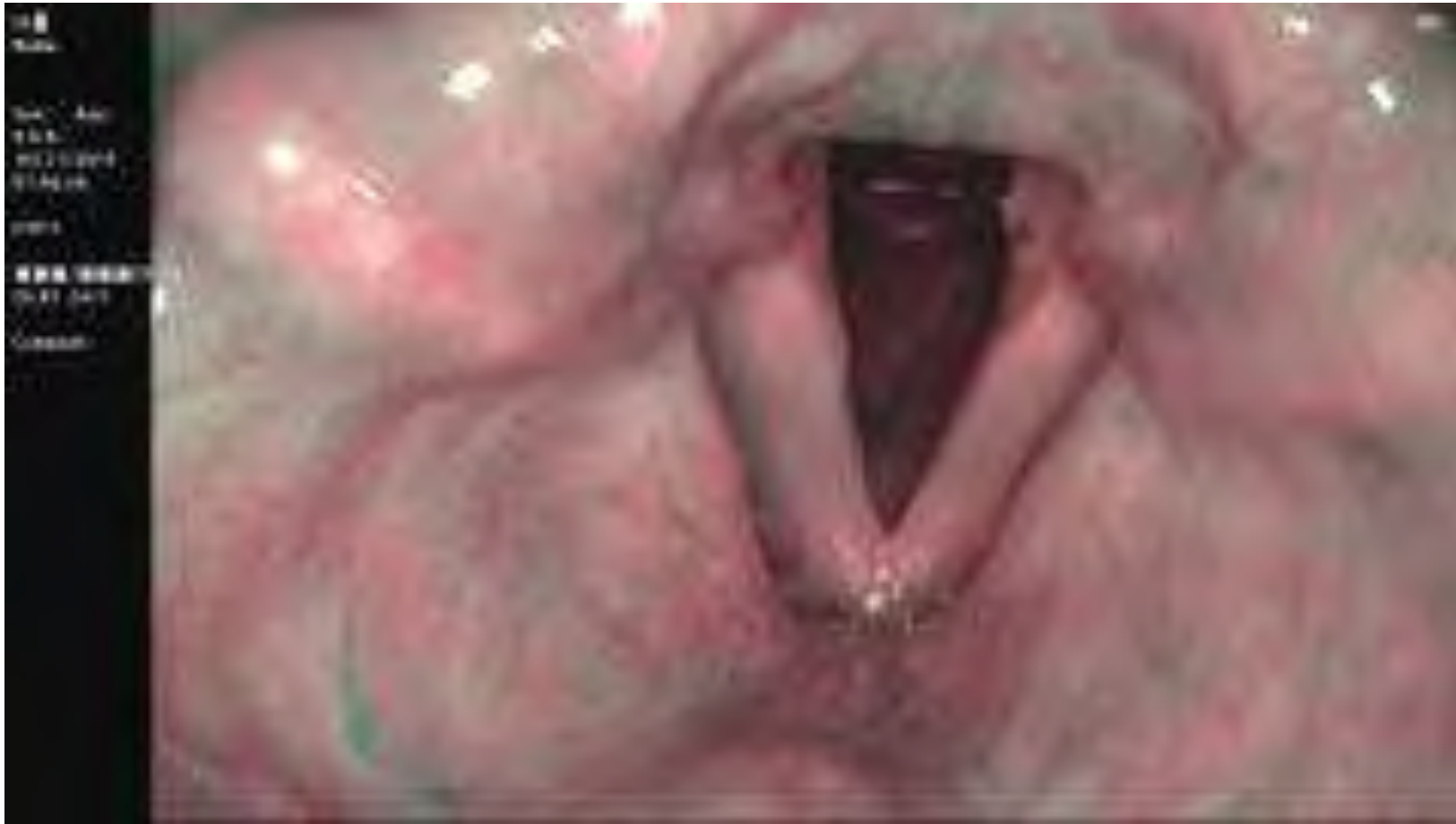
Case 5

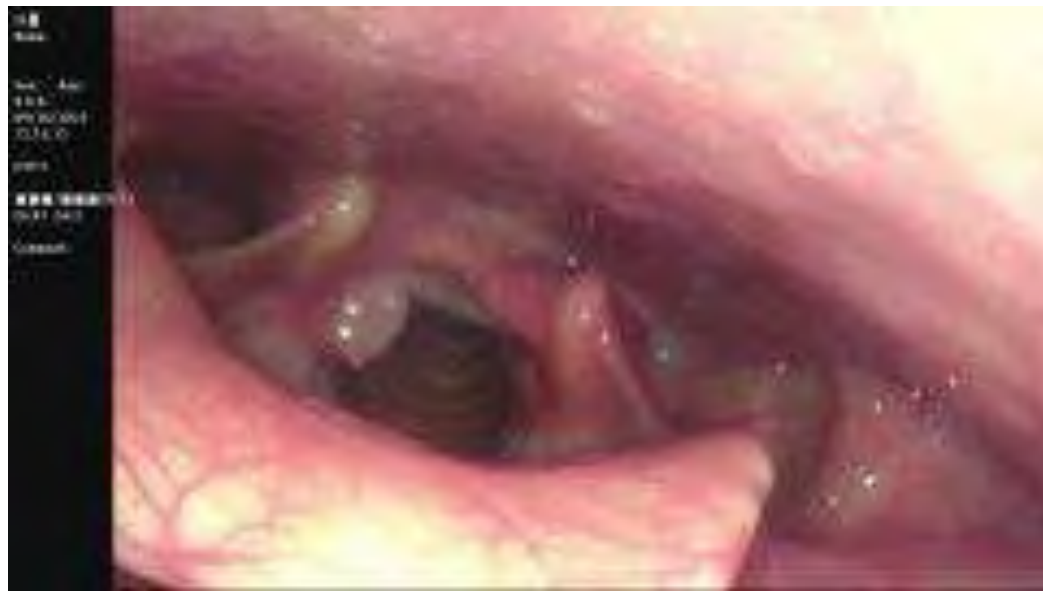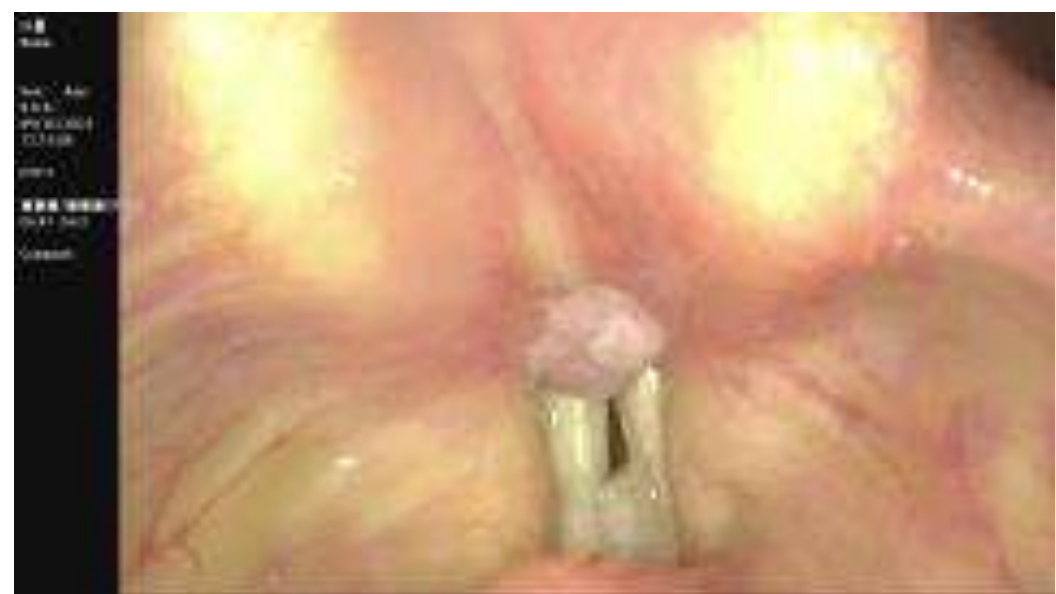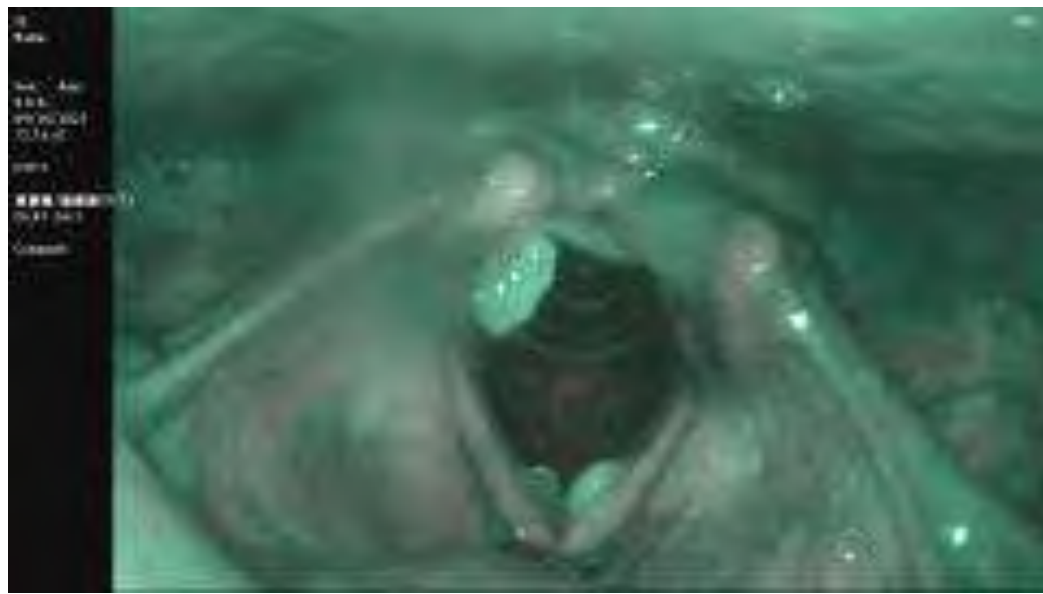
- Uneventful intubation

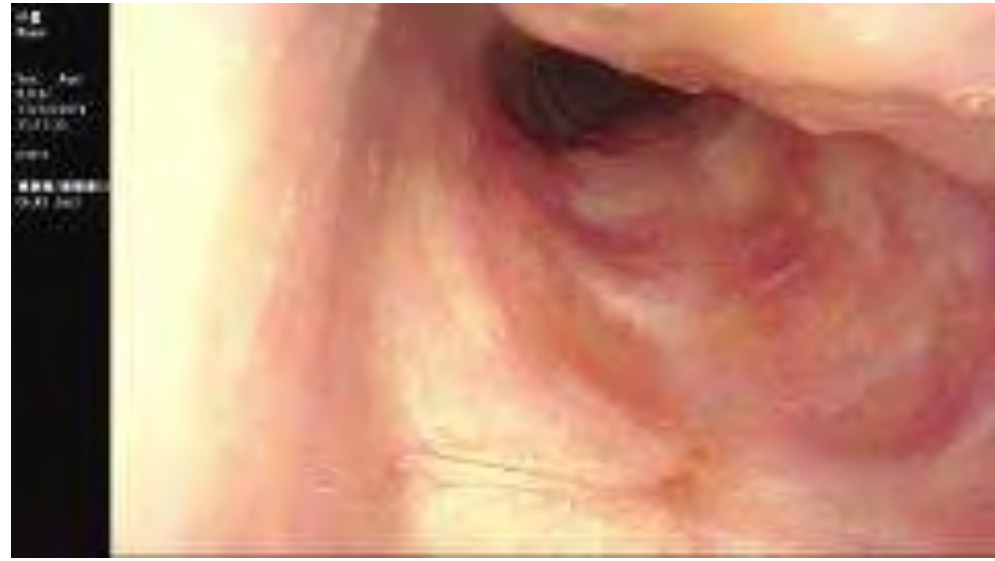
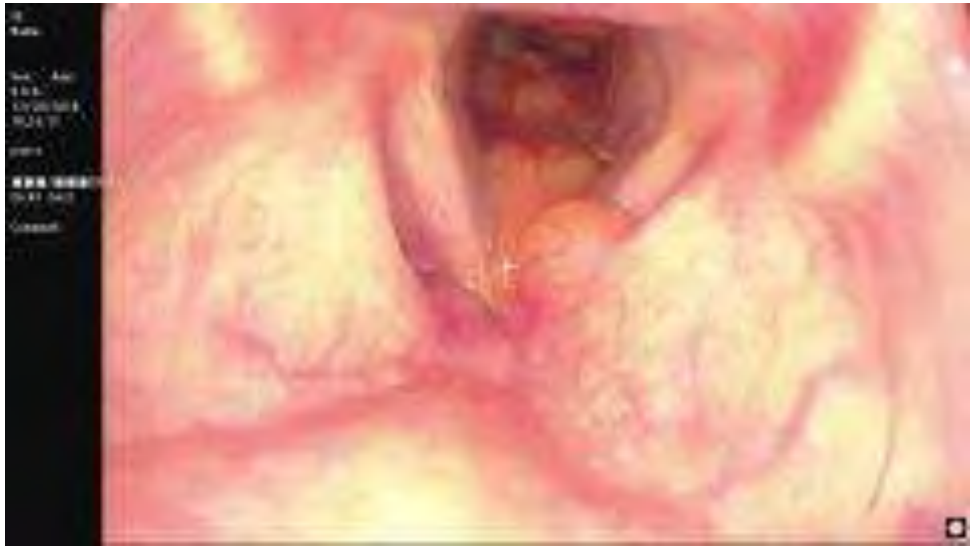

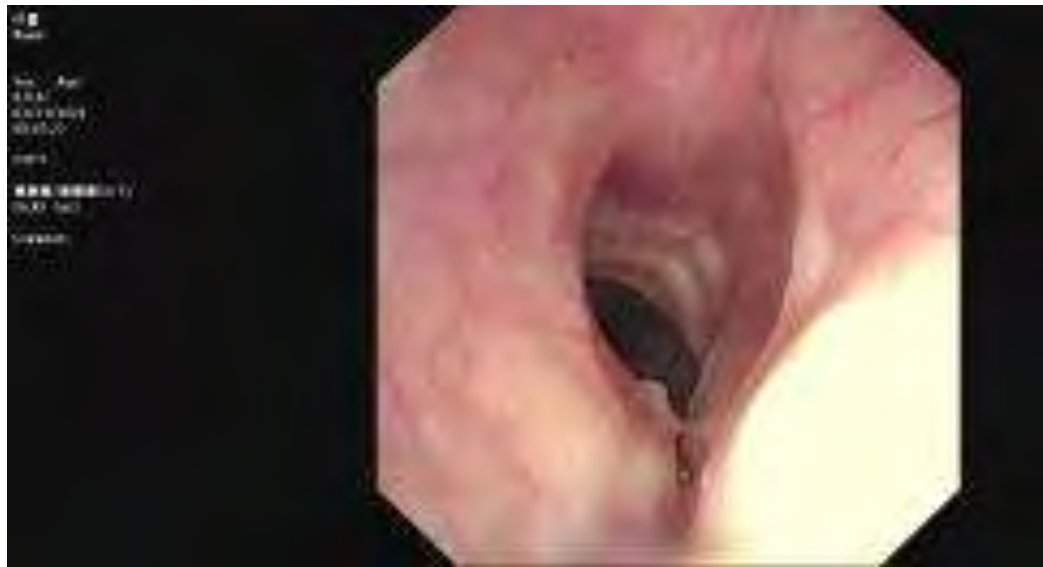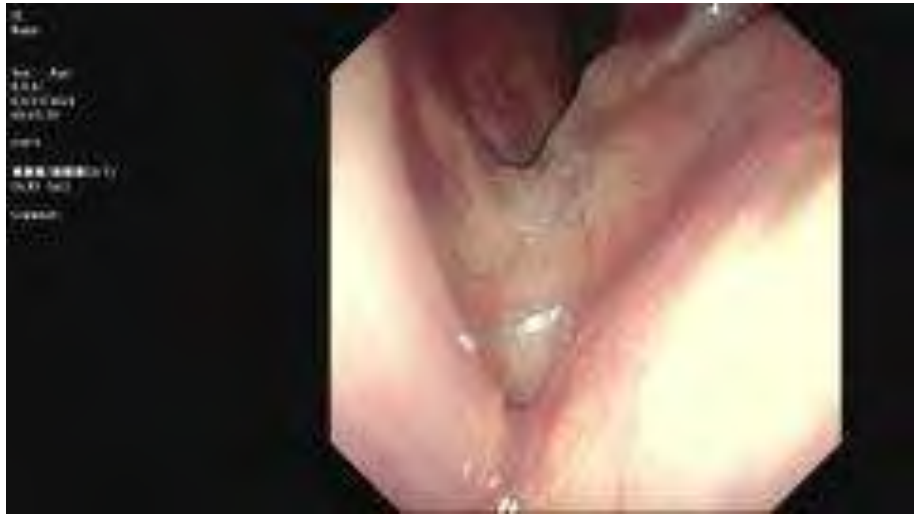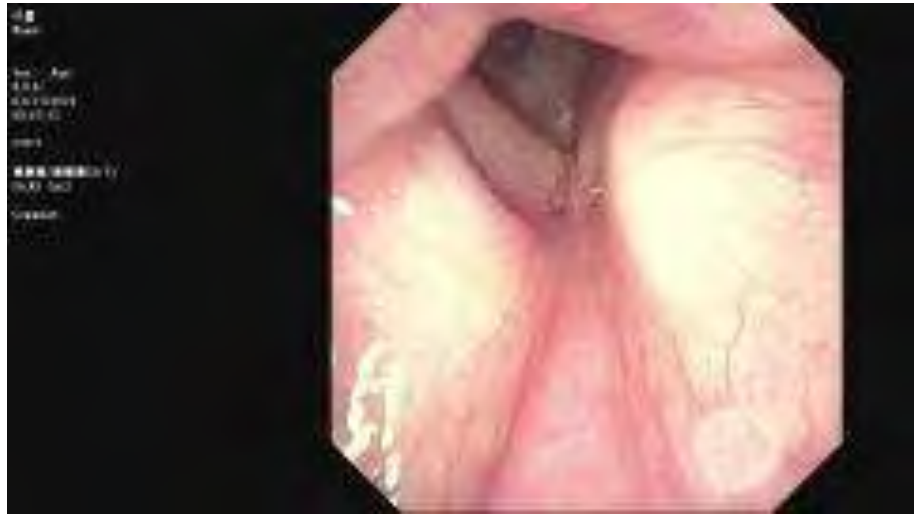Case 5

- Uneventful intubation





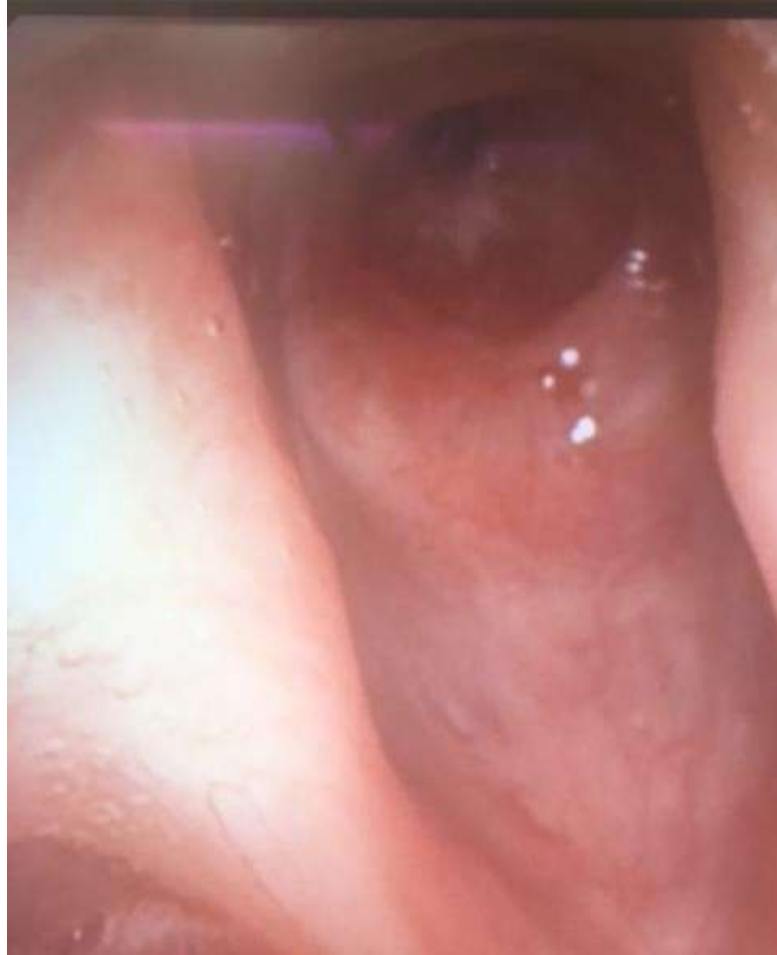



ID: [redacted]
Name: [redacted]
Sex: [redacted] Age: [redacted]
D.O.B.: 03/21/2024
08:05:52
CVP:1
[redacted]/[redacted](0/1)
EtiAS Car:2
Comment:

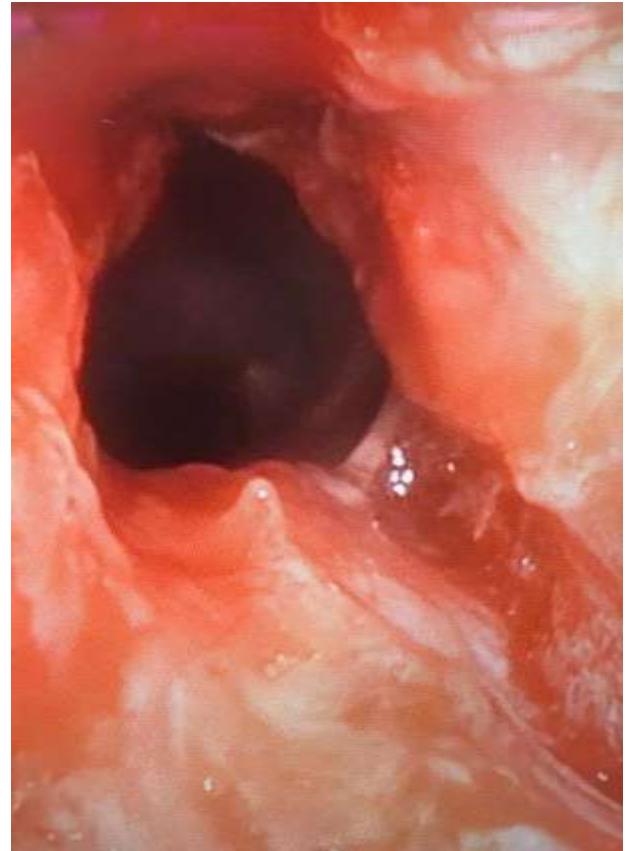
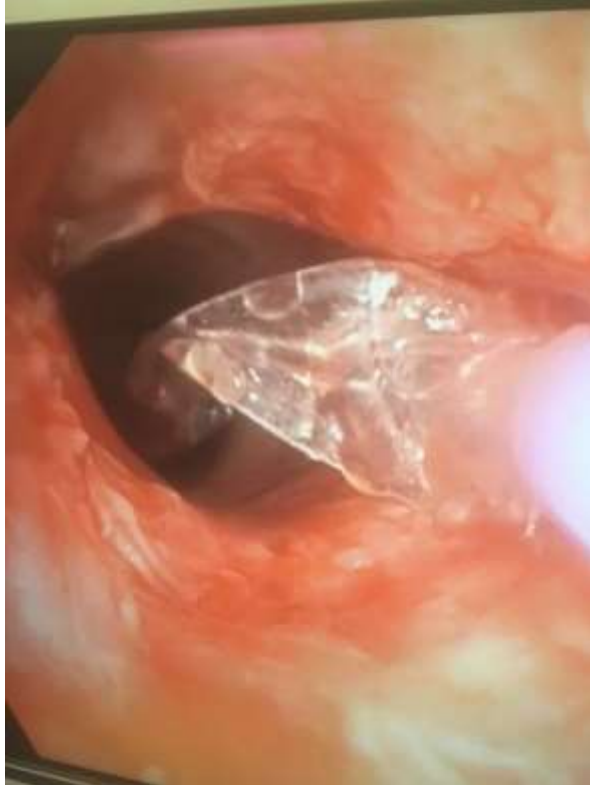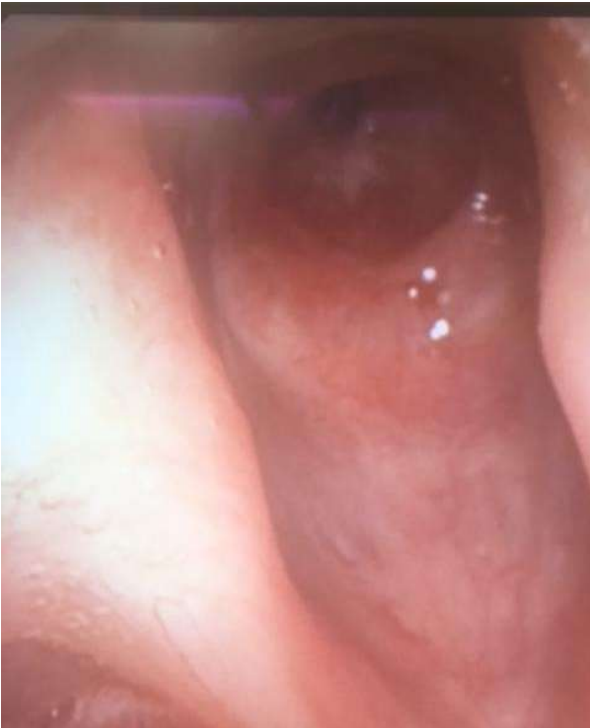Case 6

- **Stridor – prisoner**



Case 6

- Prisoner



Case 6

- Prisoner

