



Case Presentations

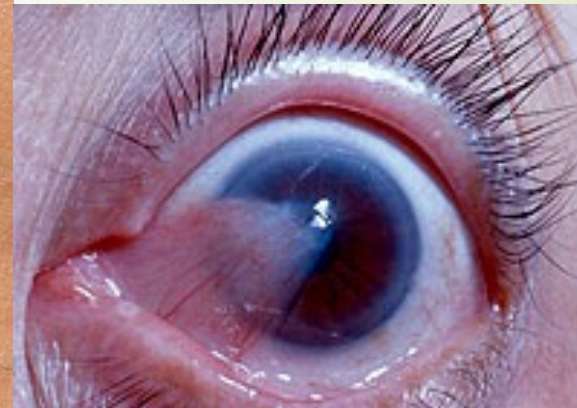
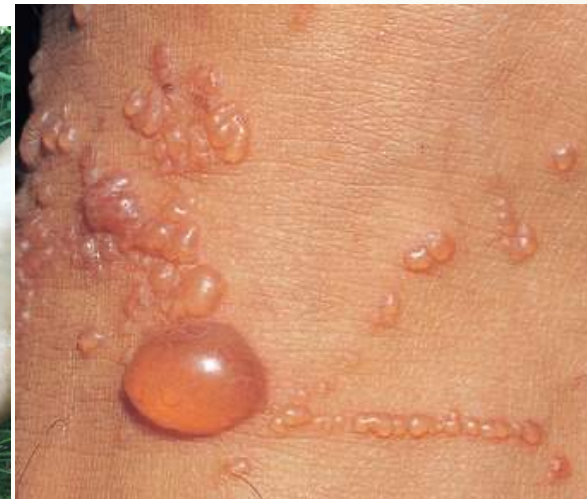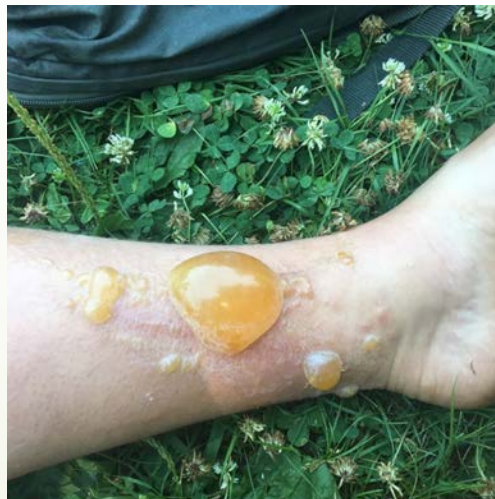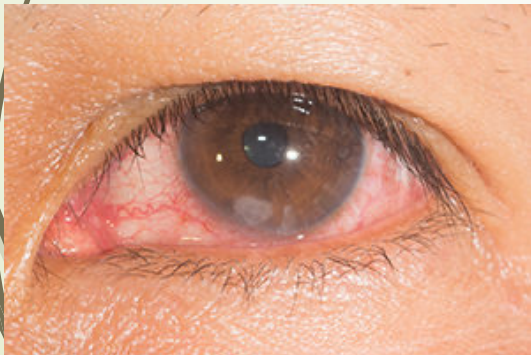
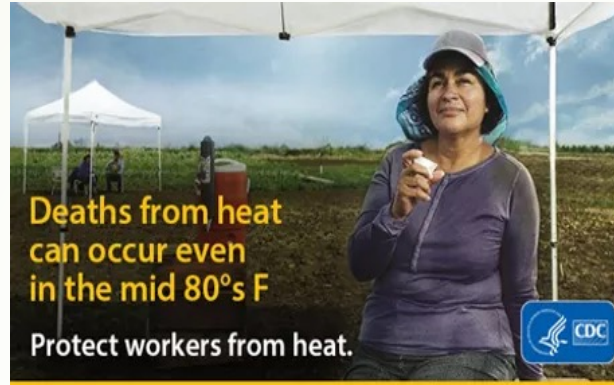CS-CASH – Agricultural Medicine Core Course

July 2021

Kelley J Donham MS, DVM, DACVPM

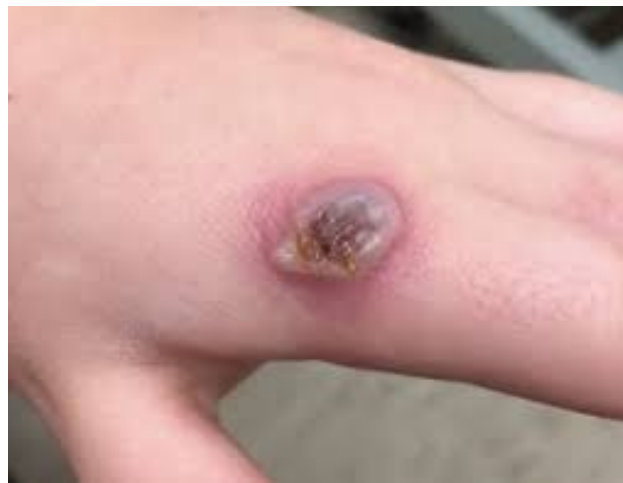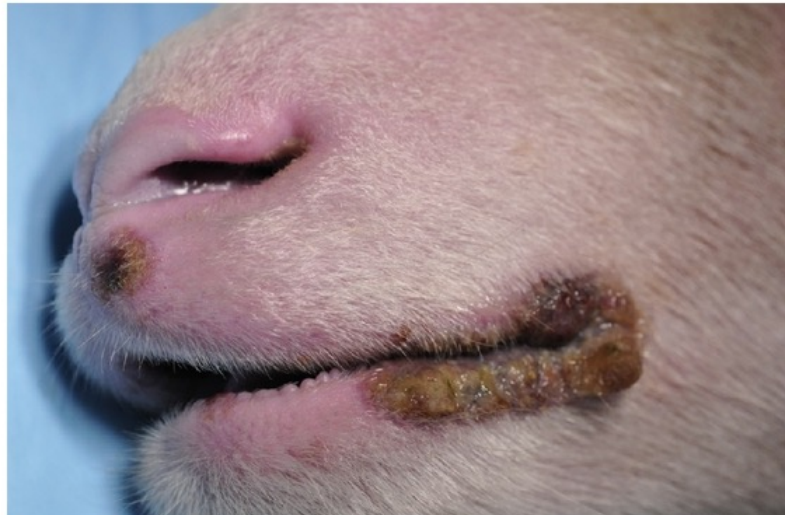Corn detasseling and health risks: Young people and immigrant farm workers –

- Heat Stress
- Corneal erosions
- Phytophoto Toxic dermatitis
- Contact allergic dermatitis
- Pterygium



Story of the Bottle – fed lamb

- ❖ 9 – year – old got a baby lamb from grandpa to raise
- ❖ Did not notice lesion on lips of the lamb
- ❖ Lesion of girls hand seen 2 weeks later
- ❖ She dreams of showing that lamb for a blue ribbon
- ❖ What is it?



First degree burn from the muffler on a 4020 tractor. How to treat it?

- ❑ First aid
- ❑ Wife want farmer to go to the doctor
- ❑ Doctor treats topical, but also, she want to give a tetanus immunization.
 - ❑ What factors should be considered to warrant a tetanus shot?

